

CASE REPORT

DOI: 10.19127/mbsjohs.1374750

Surgical Management of an Elderly Patient with Mental Nerve Hyperesthesia: A Case Report

Ömer Uranbey¹([ID](#)) Ferhat Ayrancı²([ID](#))

¹Department of Oral and Maxillofacial Surgery, Faculty of Dentistry, Ordu University, Ordu, Turkey

Received: 11 October 2023, Accepted: 07 February 2024, Published online: 28 March 2024

© Ordu University Institute of Health Sciences, Turkey, 2024

Abstract

Prolonged use of removable dentures and age-related bone remodeling can result in atrophy of the alveolar crest and lead to functional impairments and complications such as inflammation and hypersensitivity. The effectiveness of nerve transposition surgery and implant rehabilitation in reducing these complaints in atrophic mandibles is remarkable. This case study involves a 63-year old female patient who developed trigeminal nerve neuropathy, starting after use of removable dentures, with the complaint of pain around the right foramen mentale. Advanced resorption in the posterior alveolar crests of the mandible was identified through radiological examinations. After two months, there was a significant improvement in symptoms and post-operative hypoesthesia was achieved by the agency of implant rehabilitation and the inferior transposition of the right mental nerve. This case emphasizes the importance of nerve transposition surgery in severe atrophic crests, superiorly located mental foramina or hyperesthesia induced by removable prostheses.

Keywords: Bone Atrophy, Nerve Transposition, Implantology

Suggested Citation: Uranbey Ö, Ayrancı F. Surgical Management of an Elderly Patient with Mental Nerve Hyperesthesia: A Case Report Mid Blac Sea Journal of Health Sci, 2024;10(1):122-129.

Copyright@Author(s) - Available online at <https://dergipark.org.tr/en/pub/mbsjohs>

Content of this journal is licensed under a Creative Commons Attribution-NonCommercial 4.0 International License.



Address for correspondence/reprints:

Ömer Uranbey

Telephone number: +90 (543) 741 72 35

E-mail: eomeruranbey@gmail.com

INTRODUCTION

Successful dental implant placement in atrophic mandibles remains a notable clinical challenge in oral and maxillofacial surgery (1). Dental practitioners have documented the neuropathic pain associated with mental nerve hypersensitivity thoroughly which can result

from significant alveolar bone loss following long-term total denture use (2). These neuropathic disorders, notably mental nerve hypersensitivity, can significantly impair a patient's quality of life (3). Effective management of these complex cases requires finding the right balance between achieving optimal dental rehabilitation and addressing the neurological symptoms together (4).

Atrophy of alveolar crests, resulting from long-term use of removable prostheses and the effects of aging on bone remodeling, exacerbates these complaints. Impaired chewing and disharmony of the prostheses may cause inflammation in the oral cavity, hyperesthesia, and pathological fractures (5). Nerve transposition surgery and implant rehabilitation can reduce the incidence of these complications in cases of atrophic mandibles (6).

This case report analyzes a combined approach of dental implant placement in conjunction with mental nerve transposition in a patient with an atrophic mandible and hyperesthesia of the mental nerve.

CASE

A 63-year-old female patient was admitted to our clinic with a complaint of pain in the region surrounding the right foramen mentale. The study was conducted in accordance with well-established protocols. Trigger points leading to sharp pain were identified on palpation during

the clinical examination. Trigeminal neuropathy was considered when it became clear that the pain began during the function of the removable prosthesis but persisted when the prosthesis was not in use. Radiographic examination identified significant resorption in the posterior alveolar crests of the mandible (Fig 1A, 1B). A dental volumetric tomography scan located bilateral mental nerve tracts 2mm below the alveolar ridge, along with an anterior loop that included the incisive branch. The large diameter of the mental nerve was 4.10mm on the right and 3.30mm on the left side (Fig 2).

A lingualized full-thickness incision was carefully performed on the alveolar crest. The flap was reflected supraperiosteally with half thickness and the mental nerve was meticulously dissected from the surrounding tissues. Two vertical osteotomies approximately 1cm in length and a horizontal osteotomy measuring approximately 5mm wide at the base were performed to create space for the transfer of the mental nerve to its new location. The mental nerve was released at the foramen level and gently moved to its new position using a metal hook (Fig 3).

The block bone removed from osteotomy was used as a particle graft for the implantation site of an overdenture. Prior to implant placement in the anterior region of the mandible (Nucleoss® T6, İzmir, Türkiye), the right mental nerve was inferiorly transposed using piezosurgery. Following determination of the nerve's new

position, a sterile, resorbable sponge was placed on top of the nerve bundle to prevent coronal movement, and the flap was closed with a primary intention (Doğsan, Trabzon, Türkiye). The postoperative clinical course was

uneventful, and there was minimal discomfort. Ultimately, symptom reduction and hypoesthesia were achieved within 2 months after surgery (Fig 4).

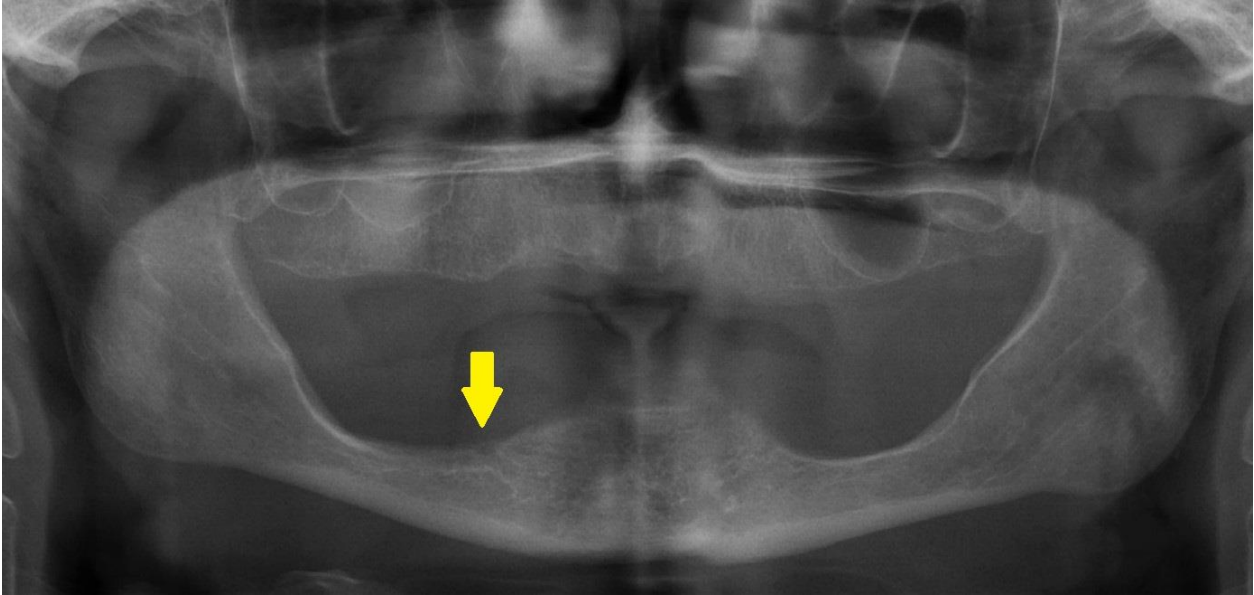


Figure 1A. Radiography showing remarkable resorption in the posterior mandible.

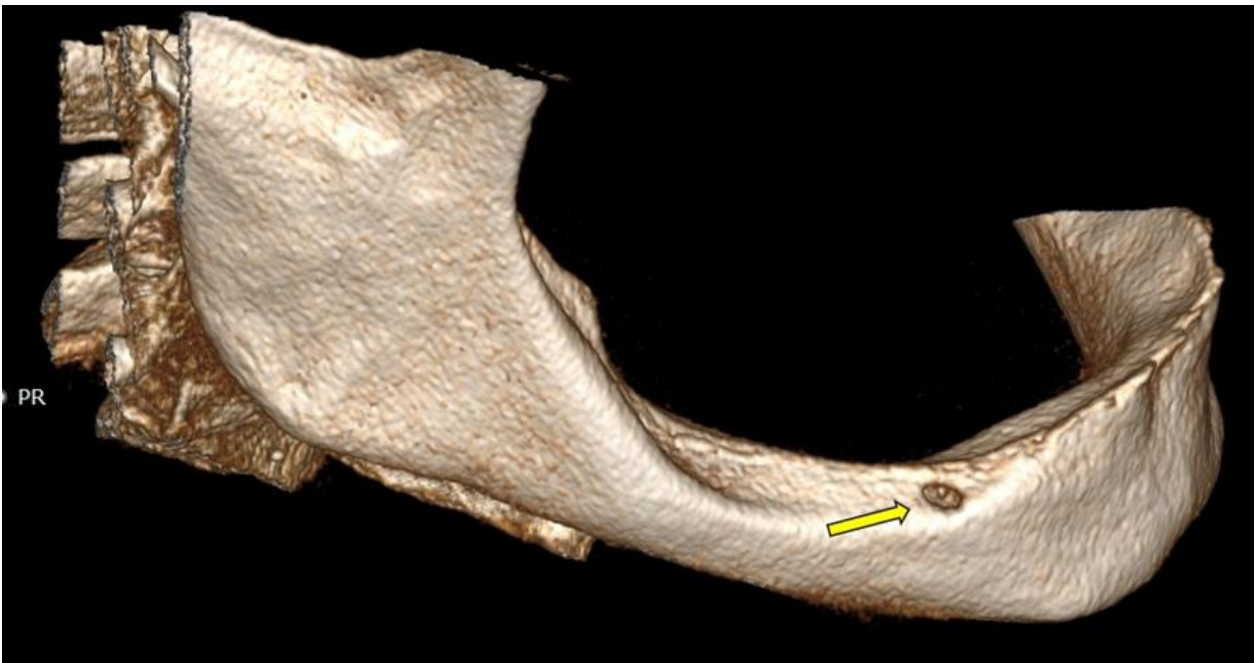


Figure 1B. 3D reconstruction of right mental foramen

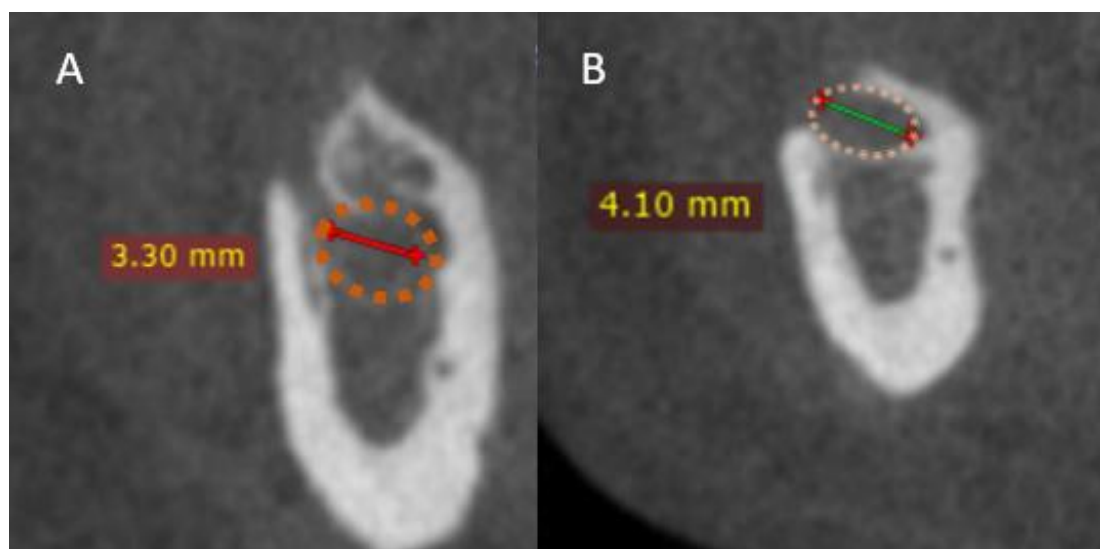


Figure 2. The large diameters of the mental nerve (Left side A, Right side B)

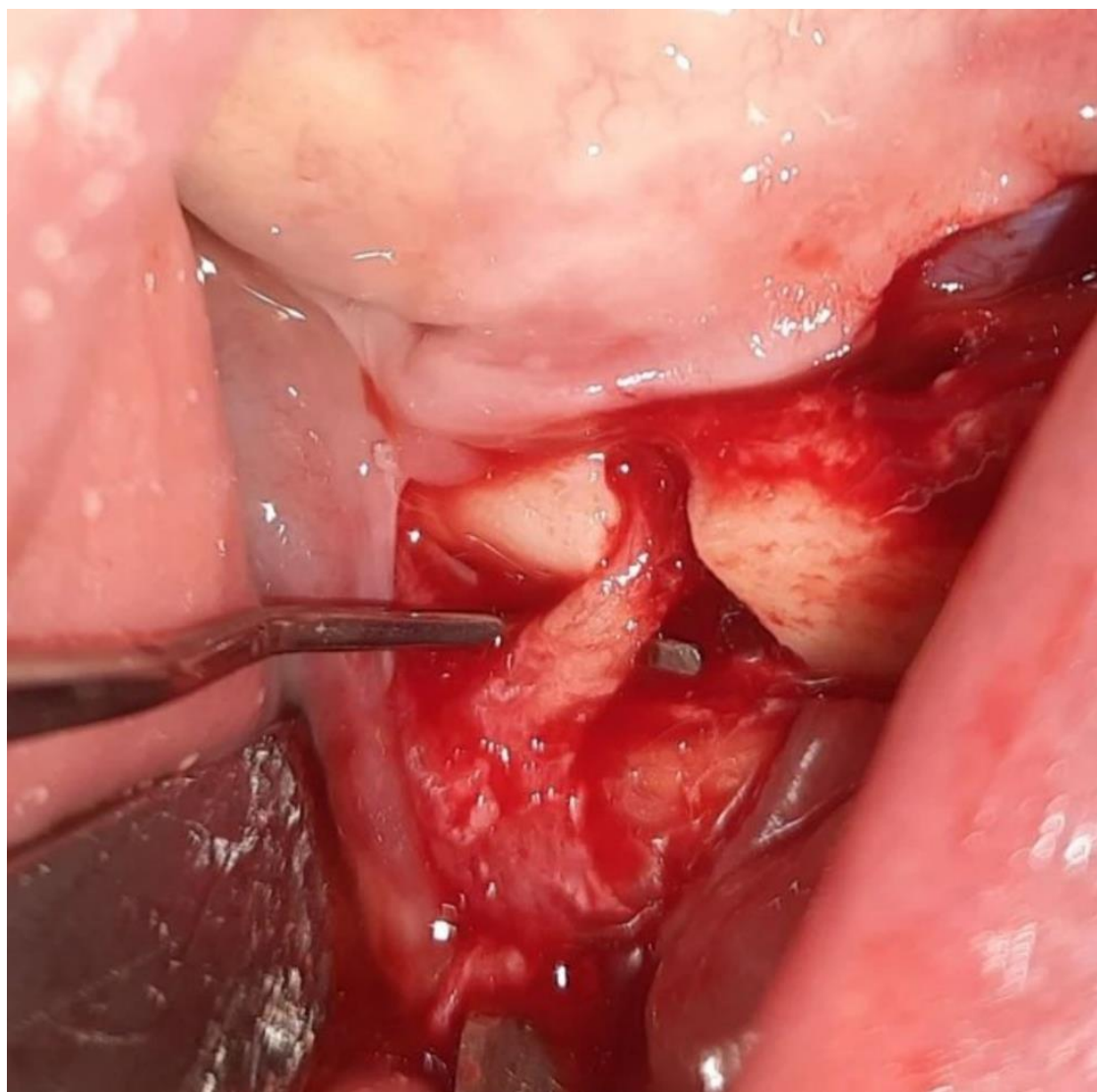


Figure 3. Retraction of mental nerve and performing a submental osteotomy.

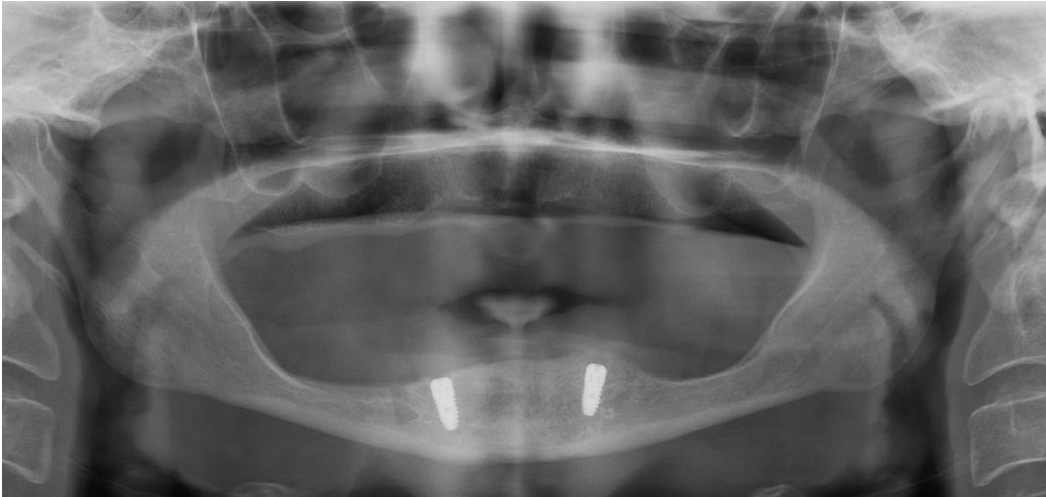


Figure 4. After the transposition, the lower placement of the mental nerve and osteotomy line can be observed.

DISCUSSION

Nerve transposition surgery is an essential step for both preprosthetic and therapeutic purposes, especially for severe cases of atrophic crests with a superiorly located mental foramen or hyperesthesia caused by removable prostheses (7). However, in such cases, surgical procedures may lead to nerve-related complications. Despite this, some authors advocate for vertical bone augmentation between the mental foramina rather than nerve transposition due to the high risk of nerve damage (2). The iliac crest is the preferred donor site for alveoplasty because of its accessibility and bone quantity (8). Considering her age and severe osteoporosis, we selected the nerve transposition for oral rehabilitation.

Our measurements of the mental foramen and the mental nerve on the right side of the mandible revealed relatively large dimensions, consistent with findings in the literature

regarding mental nerve dimensions (9, 10). This facilitated the manipulation required for the transposition. Nerve tissue trauma is unavoidable when rotary instruments and burs are used to cut bones due to the high compression and temperature generated (11). The literature indicates that ultrasonic osteotomies exhibit high success rates in this procedure (11). When using piezosurgery, the benefits of atraumatic osteotomy, such as minimal harm to surrounding soft tissues, better visibility with reduced bleeding and enhanced irrigation are noteworthy (12). In vitro, Metzger et al. found that the piezoelectric device was more invasive to the bone but carried a lower risk of nerve damage than the traditional diamond bur (11). The use of a vibrating instrument tip at different ultrasonic frequencies allows for smaller osteotomies and helps preserve vascular-nerve bundles during nerve transposition (13). Disadvantages of this

method have been reported, including prolonged operative time and excessive aerosol formation (12). In our procedure, we employed piezosurgery to inferentially transpose the mental nerve trunk. We obtained a favourable outcome in relation to the neurosensory function of the mental nerve, with the recovery of hyperesthesia at the second month and paresthesia at the fourth month after the operation. Throughout the initial year of monitoring, the patient has been successfully using overdenture prosthetics, with no recurrent neurological issues and acceptable oral functions. Nerve regeneration after compression or mild crush injuries typically takes weeks to 6 months (14). If there is no sensory recovery within this period, a permanent nerve trunk interruption can be expected (15). Literature research suggests that placing implants simultaneously with nerve transposition is advantageous, allowing for better nerve visualization while preparing the fixture location and inserting it through the mental foramen and inferior cortex (6). But on the other hand, it's important to note that removing a section of the buccal cortex during the transposition procedure combined with the placement of multiple implants may compromise structural integrity and increase the risk of potential fractures (16, 17). Nevertheless conducting separate procedures for nerve transposition and implant placement does not offer any advantages and instead

imposes an unnecessary second surgery, which could harm the patient (6).

CONCLUSION

Managing elderly patients with mental nerve hyperesthesia in the context of an extremely atrophic mandible poses a demanding and complex clinical challenge. This case report presents crucial insights into the considerations, surgical techniques and outcomes linked to the management of this condition. Prior to considering surgical intervention, a comprehensive assessment of age-related factors like changes in bone density, cognitive function, and overall health is essential. The choice to undergo surgical intervention should be based upon a thorough evaluation that takes into account the patient's medical record, ability to tolerate anesthesia and anticipated recovery outcomes (18). The surgeon must own adequate experience, anatomical proficiency and the necessary skills to manage intraoperative and postoperative complications effectively (18).

Ethics Committee Approval: The presented study is qualitative and consent was obtained by giving information about the study by one-to-one interviews with the subjects who agreed to participate. The study was carried out by paying attention to the Declaration of Helsinki.

Peer-review: Externally peer-reviewed

Author Contributions: Concept: UO, AF, Design: UO, AF, Data Collection and

Processing: UO, AF, Analysis and Interpretation: GA Writing: GA

Conflict of Interest: The authors declared no conflict of interest.

Financial Disclosure: The authors declared that this study has not received no financial support.

Acknowledgements: The authors would like to thank the people who all nurses in this study.

REFERENCES

1. Kadioglu MN, Şenturk MF, Oncul AMT, Cambazoglu M. Repositioning of the Mental Nerve in Case of Severe Mandibular Atrophy: A Case Series. *International Journal of Experimental Dental Science*. 2014;3:41-3.
2. Watanabe M, Kanno T, Sekine J. Relieving neuropathic pain of the mental nerve by vertical bone augmentation between the mental foramina: A novel technique in place of conventional inferior alveolar nerve transposition. *Journal of Oral and Maxillofacial Surgery, Medicine, and Pathology*. 2016;28.
3. Filipov I, Chirila L, Cristache CM. Rehabilitation of extremely atrophic edentulous mandible in elderly patients with associated comorbidities: a case report and proof of concept. *Head & Face Medicine*. 2021;17(1).
4. Küçük Kurt S, Biçer Aytuğ T. Inferior alveolar nerve transposition in conjunction with dental implant placement. *Atatürk Üniversitesi Diş Hekimliği Fakültesi Dergisi*. 2018;2017(2017).
5. Shibahara T, Noma H, Yamane G, Katakura A, Takasaki Y, Tamada Y. Transposition of the mental nerve and inferior alveolar nerve trunk. *The Bulletin of Tokyo Dental College*. 1996;37(2):103-7.
6. Morrison A, Chiarot M, Kirby S. Mental nerve function after inferior alveolar nerve transposition for placement of dental implants. *Journal (Canadian Dental Association)*. 2002;68(1):46-50.
7. Ferrigno N, Laureti M, Fanali S. Inferior alveolar nerve transposition in conjunction with implant placement. *The International journal of oral & maxillofacial implants*. 2005;20:610-20.
8. Pollock R, Alcelik I, Bhatia C, Chuter G, Lingutla K, Budithi C, et al. Donor site morbidity following iliac crest bone harvesting for cervical fusion: a comparison between minimally invasive and open techniques. *European Spine Journal*. 2008;17(6):845-52.
9. Chen JC, Lin LM, Geist JR, Chen JY, Chen CH, Chen YK. A retrospective comparison of the location and diameter of the inferior alveolar canal at the mental foramen and length of the anterior loop between American and Taiwanese cohorts using CBCT. *Surgical and radiologic anatomy* : SRA. 2013;35(1):11-8.

10. Muinelo-Lorenzo J, Fernández-Alonso A, Smyth-Chamosa E, Suárez-Quintanilla JA, Varela-Mallou J, Suárez-Cunqueiro MM. Predictive factors of the dimensions and location of mental foramen using cone beam computed tomography. *PloS one*. 2017;12(8):e0179704.
11. Metzger MC, Bormann KH, Schoen R, Gellrich NC, Schmelzeisen R. Inferior alveolar nerve transposition--an in vitro comparison between piezosurgery and conventional bur use. *The Journal of oral implantology*. 2006;32(1):19-25.
12. Sakkas N, Otten JE, Gutwald R, Schmelzeisen R. Transposition of the mental nerve by piezosurgery followed by postoperative neurosensory control: a case report. *The British journal of oral & maxillofacial surgery*. 2008;46(4):270-1.
13. Vasconcelos Jde A, Avila GB, Ribeiro JC, Dias SC, Pereira LJ. Inferior alveolar nerve transposition with involvement of the mental foramen for implant placement. *Medicina oral, patologia oral y cirugia bucal*. 2008;13(11):E722-5.
14. Abayev B, Juodzbals G. Inferior Alveolar Nerve Lateralization and Transposition for Dental Implant Placement. Part II: a Systematic Review of Neurosensory Complications. *Journal of oral & maxillofacial research*. 2015;6(1):e3.
15. Chrcanovic BR, Custódio AL. Inferior alveolar nerve lateral transposition. *Oral and maxillofacial surgery*. 2009;13(4):213-9.
16. Lorean A, Kablan F, Mazor Z, Mijiritsky E, Russe P, Barbu H, et al. Inferior alveolar nerve transposition and reposition for dental implant placement in edentulous or partially edentulous mandibles: a multicenter retrospective study. *International journal of oral and maxillofacial surgery*. 2013;42(5):656-9.
17. Barbu HM, Levin L, Bucur MB, Comaneanu RM, Lorean A. A modified surgical technique for inferior alveolar nerve repositioning on severely atrophic mandibles: case series of 11 consecutive surgical procedures. *Chirurgia (Bucharest, Romania: 1990)*. 2014;109(1):111-6.
18. Vetromilla BM, Moura LB, Sonogo CL, Torriani MA, Chagas OL, Jr. Complications associated with inferior alveolar nerve repositioning for dental implant placement: a systematic review. *International journal of oral and maxillofacial surgery*. 2014;43(11):1360-6.